

The Berglin apical stitch: a simple technique to straighten things out in atrial fibrillation surgery

Anders Albåge^{a,*}, Lena Jidéus^a, Hans Lidén^b and Henrik Scherstén^b,
for the Swedish Arrhythmia Surgery Group

^a Department of Cardiothoracic Surgery, University Hospital, Uppsala, Sweden

^b Department of Cardiovascular Surgery, Sahlgrenska University Hospital/Sahlgrenska, Gothenburg, Sweden

* Corresponding author. Department of Cardiothoracic Surgery, University Hospital, 751 85 Uppsala, Sweden. Tel: +46-76-7225610; fax: +46-18-509355; e-mail: anders.albage@akademiska.se (A. Albåge).

Received 8 April 2014; received in revised form 27 May 2014; accepted 5 June 2014

Abstract

In the Cox-Maze IV procedure, or in endocardial left atrial ablation, correct positioning of the surgical ablation probe within the left atrium might be difficult due to bulging or folds in the posterior left atrial wall. The Berglin apical stitch is a simple trick of the trade to create a smooth surface in the posterior left atrium that facilitates performing a safe transmural lesion and, consequently, may increase antiarrhythmic efficiency.

Keywords: Atrial fibrillation • Ablation techniques • Cryosurgery

Any surgeon operating within the left atrium (LA) via a standard left atriotomy has experienced some bulging or folds in the posterior wall of the LA, which may affect exposure. This is a particular area of interest in surgical ablation of atrial fibrillation, a treatment that is currently underused in cardiac surgery [1]. Recent guidelines and expert opinion regarding concomitant atrial fibrillation surgery advocate full biatrial lesion sets according to the classic Cox-Maze III lesion pattern [2–4]. At present, most surgeons perform these lesions endocardially with either radiofrequency or cryosurgical ablation probes, the Cox-Maze IV procedure. When performing the lower portion of the encircling box lesion between the left and right pulmonary veins, or the mitral isthmus line, bulging of the posterior atrial wall may create rather deep folds, or even double-folding of the wall, which can be difficult to flatten out with a ‘unipolar’ type of ablation probe, for example a Cryoprobe. In such cases, an incorrect placement of the probe may cause gaps in the ablation line and create possible areas of non-blockage; hence, this is a risk for an unsuccessful arrhythmia procedure. In fact, recent animal studies show that gaps in ablation lines of just a few mm showing an acute conduction block may recover with time and conduct again [5].

A very simple method to facilitate the ablation procedure in the LA is the use of a Berglin apical stitch, introduced by the late Eva Berglin, cardiac surgeon and a pioneer in Swedish arrhythmia surgery. This technique was initially developed for the classic Cox-Maze III procedure and has been used in over 200 of these cases [6]. However, it is equally feasible for endocardial left atrial ablation. After cannulation and cross-clamping, a pledgeted 3-0 Prolene stitch is placed in the epicardial fat of the apex (Fig. 1). In our experience, it is very easy to put this stitch safely to the right of the left anterior descending artery in the cardioplegic heart, with

careful attention not to tear the tissue and to avoid injury to the vessel itself. A tourniquet is then applied over the suture to make it more stable and easier to handle. After incising the interatrial groove and exposing the LA with regular fixed retractors, gentle traction of the apical suture by the assistant to elevate the apex towards the wound surface will level out the posterior wall of the LA for the surgeon. Alternatively, the suture can be locked by a haemostat to keep the uplifted apex in a desired position. Forceps can be used to momentarily flatten out folds in the atrial wall, but the apical stitch technique will give the surgeon more freedom, allowing easier and correct placement of the ablation probe (Fig. 2). After completion of the left atrial ablation, the apical

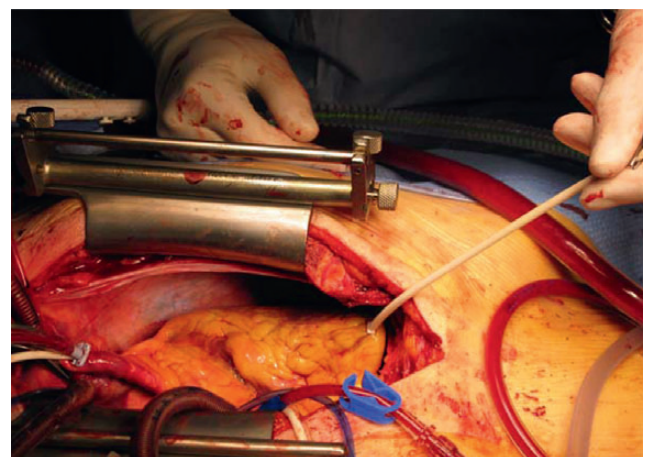


Figure 1: Gentle traction of the Berglin apical stitch will elevate the apex.

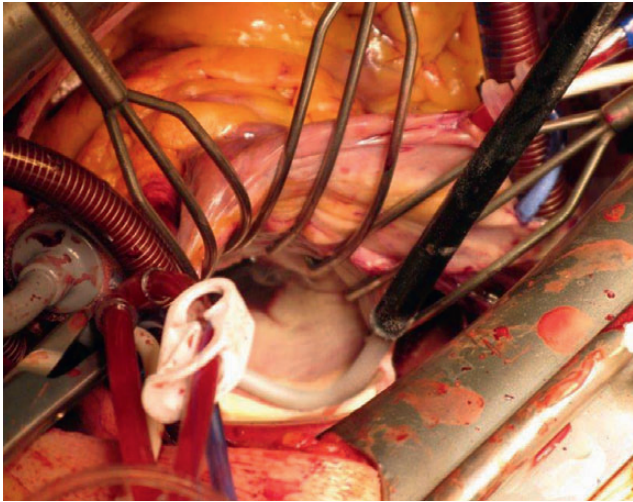


Figure 2: Folds in the left atrial posterior wall will be flattened out and allow for correct placement of the ablation probe.

suture is simply tied down and checked for bleeding. The rest of the operation is then performed in the normal fashion.

In our experience, the Berglin apical stitch is a very simple and ingenious trick of the trade to create a smooth surface in the posterior LA that facilitates performing safe transmural ablation lesions in this area. This may in turn increase the antiarrhythmic efficiency of the procedure. We have found no adverse effects with this technique and recommend its use in concomitant atrial fibrillation ablation.

ACKNOWLEDGEMENTS

We acknowledge the vast contributions of Eva Berglin to cardiac surgery in Sweden and to arrhythmia surgery in particular, for her dedicated work, mentorship and support.

Conflict of interest: none declared.

REFERENCES

- [1] Ad N, Suri RM, Gammie JS, Sheng S, O'Brien SM, Henry L. Surgical ablation of atrial fibrillation trends and outcomes in North America. *J Thorac Cardiovasc Surg* 2012;144:1051–60.
- [2] Cox JL, Schuessler RB, D'Agostino HJ Jr, Stone CM, Chang BC, Cain ME *et al.* The surgical treatment of atrial fibrillation III. Development of a definitive surgical procedure. *J Thorac Cardiovasc Surg* 1991;101:569–83.
- [3] Calkins H, Kuck KH, Cappato R, Brugada J, Camm AJ, Chen SA *et al.* 2012 HRS/EHRA/ECAS expert consensus statement on catheter and surgical ablation of atrial fibrillation: recommendations for patient selection, procedural techniques, patient management and follow-up, definitions, endpoints, and research trial design. *J Interv Card Electrophysiol* 2012;33:171–257.
- [4] Swedish Arrhythmia Surgery Group, Ahlsson A, Jidéus L, Albåge A, Källner G, Holmgren A, Boano G *et al.* A Swedish consensus on the surgical treatment of concomitant atrial fibrillation. *Scand Cardiovasc J* 2012;46:212–8.
- [5] Ranjan R, Kato R, Zviman MM, Dickfeld TM, Roguin A, Berger RD *et al.* Gaps in the ablation line as a potential cause of recovery from electrical

isolation and their visualization using MRI. *Circ Arrhythm Electrophysiol* 2011;4:279–86.

- [6] Johansson BI, Väärt O, Edvardsson N, Nyström B, Scherstén H, Karlsson T *et al.* Low mortality and low rate of perceived and documented arrhythmias after Cox Maze III surgery for atrial fibrillation. *Pacing Clin Electrophysiol* 2014;37:147–56.

eComment. The Berglin apical stitch: a simple technique to straighten things out in atrial fibrillation surgery?

Authors: Leo A. Bockeria, Andrey A. Filatov and Alexey S. Covalev
Bakoulev Scientific Center for Cardiovascular Surgery, Moscow, Russia.
doi: 10.1093/icvts/ivu283

© The Author 2014. Published by Oxford University Press on behalf of the European Association for Cardio-Thoracic Surgery. All rights reserved.

It's no secret that there are a lot of challenging aspects in concomitant surgical atrial fibrillation ablation. Among them, giant left atrium, insufficient sources of energy, anatomical disorders and others. The authors of this article [1] describe the real efforts made to solve one of these problems, suggesting an easy, convenient and cheap way to increase the efficacy of Maze procedures. We believe that it can be used in contemporary surgery due to all of those advantages.

Many controversies remain regarding the optimal management of AF, and the solution lies deeper in the electro-anatomical mechanisms. First of all, there are the anatomical features and abnormalities. The efficacy of the Maze procedure is not solely dependent on the posterior wall thickness. As discussed in the review by Shotten *et al.*, the left atrium has a heterogeneous structure with massive fibre orientation, such as the crista terminalis, the bundle of Bachmann, and the area in between the pulmonary veins [2]. Sometimes it is challenging to interrupt these structural connections even with cryo devices, not to mention catheter ablation.

Secondly, there is the insight into electrical patterns. We are not discussing directly the mechanisms of induction and maintenance. The aim of the Maze procedure according to the authors is to eliminate triggers or rotors and decrease the substrate. But it is still not proven that the way of excitation lies intramurally or endocardially, or that the epicardial breakthrough totally coincides with endocardial focus [3].

The last but very important aspect is the source of energy which is used during concomitant AF surgery. Many devices are available, such as cryoballoons, clamps, uni- and bipolar RF pens, ultrasound, lasers, etcetera, each of which has its own advantages and disadvantages [4]. But the most valuable thing is the possibility of creating a totally transmural lesion. Even with a proper ablation device, it is sometimes impossible to reach the required depth of damage to the myocardium, particularly with the wrong type of ablation system. And we are closing a loop exactly in this place - this problem depends on the anatomical features.

In conclusion, we believe that the Berglin apical stitch is a very interesting and novel method of assistance during concomitant Maze procedure. And our opinion is that it can be used to provide a better view and efficacy, but only if surgeon is completely certain of the accuracy of the chosen device, the absence of structural abnormalities and the selection of the area to ablate.

Conflict of interest: none declared.

References

- [1] Albagea A, Jideusa L, Lidenb H, Scherstenb H. The Berglin apical stitch: a simple technique to straighten things out in atrial fibrillation surgery. *Interact CardioVasc Thorac Surg* 2014;19:685–6.
- [2] Shotten U, Verheule S, Kirchhof P, Goette A. Pathophysiological mechanisms of atrial fibrillation: a translational appraisal. *Physiol Rev* 2011;91:265–325.
- [3] de Groot NM, Houben RP, Smeets JL, Boersma E, Schotten U, Schalij MJ *et al.* Electropathological substrate of longstanding persistent atrial fibrillation in patients with structural heart disease: epicardial breakthrough. *Circulation* 2010;122:1674–82.
- [4] Nakamura Y, Kiaii B, Chu M. Minimally invasive surgical therapies for atrial fibrillation. *ISRN Cardiol* 2012;2012:606324; doi:10.5402/2012/606324.